



ELSEVIER



12

Medical and surgical management of adenomyosis

Cynthia Farquhar*^{*} MChB, MD, FRANZCOG, CREI, MPH

Postgraduate Professor of Obstetrics and Gynaecology

Department of Obstetrics and Gynaecology, National Womens' Health at Auckland, City Hospital,
University of Auckland, Private Bag 92019, Auckland, New Zealand

Ivo Brosens MD, PhD, FRCOG

Professor

Leuven Institute for Fertility and Embryology, Leuven, Belgium

Adenomyosis of the uterus is a common condition amongst women in their reproductive years. It is defined as the presence of heterotopic endometrial glands and stroma in the myometrium with adjacent smooth muscle hyperplasia. The common presenting symptoms are painful and heavy periods and infertility, although many women are asymptomatic. Adenomyosis is thought to affect 1% of women and is typically diagnosed in the 4th and 5th decades of life. The aetiology is unclear, and until recently a diagnosis was made only after invasive and destructive surgery. With the advent of improved imaging of the pelvic organs, and in particular magnetic resonance imaging, the diagnosis of adenomyosis is being made more frequently. Unfortunately, because the disease has been infrequently diagnosed prior to hysterectomy, there are few well-designed studies of medical or surgical management. Management with hormonal treatment that aims to reduce the proliferation of endometrial cells is promising, but there is a paucity of well-designed studies to guide treatment. Hysterectomy or use of the levonorgestrel intrauterine system (LNG-IUS) remains the mainstay of treatment.

Key words: adenomyosis; medical and surgical management.

Adenomyosis of the uterus is a common condition amongst women in their reproductive years. It is defined as the presence of heterotopic endometrial glands and stroma in the myometrium with adjacent smooth muscle hyperplasia. The common presenting

* Corresponding author. Tel.: +64-0-3737599 ext. 89481/Secretary ext. 89493; Mobile: +64-21-995-414; Fax: +64-9-3035969.

E-mail address: c.farquhar@auckland.ac.nz (C. Farquhar).

symptoms are painful and heavy periods and infertility, although many women are asymptomatic. Adenomyosis is thought to affect 1% of women and is typically diagnosed in the 4th and 5th decades of life. The aetiology is unclear, and until recently a diagnosis was made only after invasive and destructive surgery. With the advent of improved imaging of the pelvic organs, and in particular magnetic resonance imaging, the diagnosis of adenomyosis is being made more frequently. Unfortunately, because the disease has been infrequently diagnosed prior to hysterectomy, there are few well-designed studies of medical or surgical management.

PATHOLOGICAL CONSIDERATIONS

Adenomyosis is defined as the presence of a poorly circumscribed area of smooth muscle cells, stroma and endometrial glands invading the uterine smooth muscle layers of the myometrium. The degree of invasion is variable and can involve the whole of the myometrial layer, from endometrium to serosal surface. The glandular extension must be >2.5 mm below the endometrial–myometrial interface in order to make the diagnosis.¹ Several histological diagnostic criteria and classification systems are in use.² The posterior wall of the myometrium is more often involved than the anterior wall. The uterine size is often moderately increased, and this probably results from hyperplasia of the smooth musculature.

Previously adenomyosis has been a histological diagnosis typically made only after hysterectomy or invasive surgery. With the improvement in imaging, especially magnetic resonance imaging (MRI), criteria have been established that allow the diagnosis to be made *in vivo*.³ This also allows conservative treatment to be an option.

Many of the symptoms of adenomyosis overlap with those of endometriosis. Most gynaecologists consider that adenomyosis arises as the result of invasion from the endometrial layer. However, another explanation is that endometrial glands within the rectovaginal septum invade the myometrial layer, and this is now also called adenomyosis or rectovaginal adenomyosis.⁴

PREVALENCE STUDIES

The pathological features of adenomyosis are present in 20–35% of women undergoing hysterectomy for benign gynaecological disorders.⁵ The clinical presentation of the woman with adenomyosis is often mixed. Whilst dysmenorrhoea is the most common presenting symptom, menorrhagia and infertility are increasingly recognized as being part of the symptom complex. In addition, many women are recognized as having adenomyosis only after hysterectomy. However, many women are diagnosed with adenomyosis who do not have this symptom complex, and the relationship between symptoms and pathology is by no means clear. More recent MRI studies have suggested that it is more often than not present in women with coexisting endometriosis.⁶

METHODOLOGY

The Cochrane Library (Issue 1, 2005), MEDLINE (1990–April 2005), and EMBASE (1990–April 2005) were searched using the search terms 'adenomyosis'. The reference lists of articles identified by this search strategy were searched for further studies. Each study was assessed for study design, and preference was given to randomized controlled trials.

MANAGEMENT STRATEGIES FOR ADENOMYOSIS

Today the real challenge is tailoring treatment – whether medical, surgical or combined – to the individual woman's need, depending on the type and extent of disease. Preoperative diagnosis of endometriosis and adenomyosis by imaging techniques is increasingly feasible.

MEDICAL TREATMENTS

With the establishment of diagnostic criteria for imaging studies, it is now possible to offer women the options of non-surgical treatments. These range from local treatments such as intrauterine devices (IUDs) to systemic preparations of gonadotrophin-releasing hormone (GnRH) analogues.

The levonorgestrel intrauterine system (LNG-IUS)

Although the intrauterine device was originally designed as a method of contraception, the addition of progesterone to the device means that it can now be used for managing menstrual disorders. Although the majority of the studies have been in women with heavy menstrual bleeding, LNG-IUS also has the potential to be used in women with endometriosis and adenomyosis. The LNG-IUS releases 20 µg levonorgestrel per day and has been shown to result in a profound reduction in menstrual blood loss in women with heavy menstrual bleeding; 20% of the women using the LNG-IUS were amenorrhoeic after 1 year's use while still continuing to ovulate.⁷ The LNG-IUS, which has contraceptive efficacy for 5 years, has also been reported to improve dysmenorrhoea. It is likely that some of the women with dysmenorrhoea may also have undiagnosed adenomyosis. A major disadvantage of the device is frequent and variable intermenstrual bleeding and spotting during the first few months of use.

There are several mechanisms that could explain the role of the LNG-IUS in adenomyosis. Use of the LNG-IUS is associated with decidualization of the endometrium followed by atrophic changes.⁸ As a result there is a marked reduction in menstrual blood loss. Levonorgestrel also acts directly on the adenomyotic deposits. Down-regulation of oestrogen receptors, which are present in both glandular and stromal endometrial tissues, occurs shortly after placement of the device and persists for at least the first year of use.⁹ The adenomyotic deposits then reduce in size, and as a result of these shrinking deposits, uterine contractility improves and the uterine size decreases. Local LNG levels following uterine placement of the LNG-IUS result in very high endometrial levels of LNG compared to those in serum.¹⁰ By contrast, subdermal implants of LNG do not produce these high endometrial levels.¹¹ LNG-IUS also improves dysmenorrhoea which is thought to occur because of the reduction of prostaglandin production within the endometrium.¹² Reduction in the size and activity of deposits of adenomyosis may also account for the improvement in dysmenorrhoea. This reduction is also reported in women without adenomyosis.⁷

Use of the LNG-IUS in women with endometriosis and adenomyosis has been infrequently documented. There is only one randomized controlled study that has suggested benefit in women with endometriosis.¹³ Forty women were randomized to either LNG-IUS or no treatment following surgery for endometriosis. Moderate or severe dysmenorrhoea recurred in two of 20 (10%) women in the postoperative LNG-IUS group compared with nine of 20 (45%) women in the surgery-only group.

Although it is not specifically reported whether any of these women had adenomyosis as well as endometriosis, it seems likely that a proportion of the women would.

LNG-IUS has also been used with good effect in women with rectovaginal endometriosis.¹⁴ In a study of 11 women with rectovaginal endometriosis who used the LNG-IUS for 12 months, dysmenorrhoea, pelvic pain, and deep dyspareunia greatly improved and the size of the endometriotic lesions was significantly reduced by treatment.¹⁴ However, it is not clear whether some of these women had coexisting adenomyosis.

There are also case series of women with adenomyosis and menorrhagia who benefited from the use of LNG-IUS.^{8,15} In one series 25 women with menorrhagia who were also found to have adenomyosis on the basis of ultrasound were treated with the LNG-IUS;⁸ 12 months after insertion, the amenorrhoea rates were 10%, with only one expulsion.

In a retrospective comparative report of 95 women with adenomyosis who were treated with endometrial resection, 53 women had the LNG-IUS inserted immediately and 42 women were used as controls. The diagnosis of adenomyosis was made only when endometrial cells with stroma were detected from the basal layer of the myometrium occupying at least half of a lower-power microscopic field and delimited by hypertrophied bands of smooth muscle.¹⁶ After 1 year of follow-up, all women in the LNG-IUS group were amenorrhoeic compared to only 9% of women in the control group. Of women in the LNG-IUS group, 90% reported disappearance of their dysmenorrhoea compared to only 20% of women in the control group. Eight women in the control group required a second endometrial resection, whereas none in the LNG-IUS group did. Immediate post-surgical insertion of the LNG-IUS did not result in any serious adverse events, and the device did not have to be removed in any of the women. The rates of amenorrhoea in this study are considerably higher than usually reported with the LNG-IUS, and this may be explained by the higher myometrial levels of levonorgestrel that can be achieved once the endometrium is removed.

The combination of endometrial resection and the LNG-IUS is a possible alternative to hysterectomy in women who have completed their childbearing, while in women who wish to retain their fertility the LNG-IUS alone is a reasonable choice. However, it should be emphasized that these women had menorrhagia and the diagnosis of adenomyosis was not necessary in order to commence therapy with the LNG-IUS.

The most frequent problem of the LNG-IUS is irregular bleeding during the initial few months of treatment. During this time the endometrium is being shed as a result of decidualization and atrophy. Other reported side-effects include follicular cysts, acne and breast tenderness. These effects generally resolve after the first 3 months.

Danazol-loaded intrauterine devices

A danazol-loaded IUD has been developed by covering a contraceptive IUD (FD-I, Fuji Latex, Tokyo, Japan) with silicone rubber (MDX 4-4210; Dow Corning Corporation, Midland, MI, USA) containing 300–400 mg danazol. The size of the device is quite similar to the copper-T IUD but is much thicker in the antero-posterior diameter. Because of the large volume of the device, cervical dilatation may be needed for proper insertion and perfect intrauterine placement. Serum levels of danazol remained below the detection threshold and therefore none of the systemic side-effects associated with oral danazol occurred. This device has been tested in 14 women with dysmenorrhoea, hypermenorrhoea or infertility; nine of them had complete resolution of their

dysmenorrhoea, and 12 had complete resolution of their menorrhagia. In two women no change occurred.¹⁷ A prospective, non-comparative study of 21 symptomatic women with adenomyosis found complete relief of menstrual pains and dysmenorrhoea in 17 (81%) and improvement of menstrual bleeding in 16 (76%) after 6 months.¹⁸ No systemic side-effects known with danazol occurred during the study. The only observed disadvantages of the danazol-loaded IUD in this series was uterine spotting and spontaneous expulsion.

GnRH agonists

GnRH agonists bind to the GnRH receptor in the pituitary gland which results in down-regulation of GnRH activity, inducing a reversible state of medical menopause. Oestrogen levels fall, which induces atrophy of the adenomyotic nodules, which in turn results in a reduction in the uterine size. The most common side-effects result from the lowered oestrogen levels and include hot flushes and reduced bone mineral density. Once the treatment is stopped the adenomyosis returns and therefore there is little hope of a permanent cure with this approach. However, there is the potential for preoperative treatment with GnRH agonists followed by excision of the nodules. It is likely that the uterus is weakened by surgery, and in any future pregnancies uterine rupture may be a risk. There are only a few reports of this approach.^{19,20} The length of the treatment is usually 3–6 months. Amenorrhoea is induced during treatment. Laparoscopic excision has been used following the GnRH agonist. Another possible advantage of GnRH agonists prior to surgery will be reduced blood loss and less tissue trauma.

Aromatase inhibitors

Endometriosis and adenomyosis are generally considered to be oestrogen-dependent diseases. One of the most important advances in the understanding of these diseases has been the discovery that both eutopic and ectopic endometrium in affected women express aromatase P450, the enzyme that converts C19 androgens to C18 oestrogenic steroids.^{21,22} Aromatase P450 expression in the human endometrium is thought to be restricted to women with proliferative reproductive tract disorders such as endometriosis, adenomyosis and leiomyomata. In addition, oestrone sulphatase has also been localized in uterine endometrium and adenomyosis.²³

Ectopic endometrium produces oestrogen which has important consequences for both medical and surgical treatments. It tends to support the view that severe disease requires complete excision to minimize the risk of recurrence. However, in severe endometriosis or in uterine adenomyosis complete excision cannot be guaranteed. Therefore it provides a rational explanation for the recent finding that the suppression of both ovarian and local oestrogen biosynthesis with a GnRH agonist and an aromatase inhibitor significantly reduces the risk of recurrence after conservative surgery. In a randomized, double-blind, placebo-controlled trial Soysal et al²⁴ found that after conservative surgery for severe endometriosis the addition of anastrozole to goserelin reduced the risk of recurrence and increased the maintenance of efficacy of the surgical treatment for at least 24 months following medical treatment. The combined treatment of an aromatase inhibitor with a GnRH agonist or an oral contraceptive²⁵ can be added to the arsenal of therapeutic options for severe endometriosis in premenopausal women.

SURGICAL TREATMENTS

Hysterectomy

For more than a century hysterectomy has been both the primary diagnostic and the therapeutic strategy for uterine adenomyosis. Vaginal hysterectomy is preferable to abdominal hysterectomy because of lower morbidity and faster recovery. However, the decision to perform a hysterectomy abdominally or vaginally is often based not only on the indication but also on the familiarity and experience of the individual surgeon. In a large comparative study of complications of vaginal hysterectomy in patients with leiomyomata and in patients with adenomyosis, Furuhashi et al²⁶ found that women with adenomyosis had a significantly higher risk of bladder injury, while there was no difference in blood loss and operating time when the uterine weight was taken into account. The definite reason for the increased risk of bladder injury is unknown, but it may be due to the greater difficulty in identifying the supravaginal septum and the vesicovaginal and vesicocervical planes. Most cases of failed vaginal hysterectomy for uterine adenomyosis are due to associated adhesions. The use of laparoscopic-assisted vaginal hysterectomy is likely to decrease the risk of bladder injury and the failure of vaginal hysterectomy. The effect of preoperative use of GnRH agonists on reducing intraoperative complications in women with uterine adenomyosis has not been evaluated.

Conservative surgery

Conservative surgery has been introduced since imaging technology has allowed the presumptive diagnosis of uterine adenomyosis in symptomatic women who want to preserve their uterus. The current approach of conservative surgery depends on the localization of the adenomyoma and the extent of the disease. However, uterine adenomyosis is also frequently associated with other benign proliferative diseases such as uterine leiomyomata, endometriosis and adhesions. Therefore, careful preoperative evaluation of the presence and extent of other pelvic lesions by imaging techniques and endoscopy is required for optimal surgical management.

For the benefit of clinicians Cullen in 1908 distinguished three classes of uterine adenomyomata,²⁷ although he recognized that one class might imperceptibly merge into the other:

- (1) submucous adenomyomata;
- (2) adenomyomata where the uterus preserves a relatively normal contour;
- (3) subperitoneal or intraligamentary adenomyomata.

This classification, similar to the classification of uterine leiomyomata, can be used for describing the surgical approach to uterine adenomyomata (Table 1).

Submucous adenomyomata

Polypoid adenomyomata of the uterus, also known as adenomyomatous polyps, are endometrial polyps in which the stromal component is predominantly or exclusively

Table 1. Surgical management of uterine adenomyoma.

Submucous:

- adenomyomatous polyp hysteroscopic excision
- superficial adenomyosis endometrial ablation (followed by LNG-IUS)

Intramural:

- deep (>2.5 cm) adenomyosis hysterectomy
- focal adenomyoma excision/reduction, hysterectomy

Subserous or subperitoneal:

- superficial excision/excision
- retrocervical, rectovaginal laparoscopic excision

LNG-IUS, levonorgestrel intrauterine system.

composed of smooth muscle. The polypoid adenomyomata account for only 1.3% of all endometrial polyps, but are being detected with increasing frequency.²⁸ They may be pedunculated or sessile and protrude into the endocervical canal and vagina. Knowledge of the sonographic appearance of polypoid adenomyomata by the presence of cystic areas may facilitate and help distinguish these tumours from other uterine polypoid tumours.²⁹ They can, like submucous leiomyomata, be removed by hysteroscopy. The polypoid adenomyomata are frequently associated with adenomyosis in the myometrium.

Symptomatic submucous or superficial adenomyosis is usually a diffuse process involving the entire circumference of the uterine wall. Ultrasound and magnetic resonance studies have shown that in diffuse adenomyosis the posterior wall is the area most frequently and severely affected.^{30,31} Superficial submucous adenomyosis can be treated by transcervical endometrial coagulation or resection. According to data collected by Löffler (1995), the failure rate for endometrial ablation lies between 8 and 10%.³² In a study of 305 ablations Pagedas et al (1995) reported that the histological results from patients requiring hysterectomy after unsuccessful endometrial ablation showed an incidence of adenomyosis of around 75%.³³ McCausland and McCausland (1996) reported that seven out of eight cases requiring hysterectomy were found to have adenomyosis.³⁴ These reports have raised concern that the presence of adenomyosis could be responsible for many of the failures of endometrial ablation or resection. However, these authors also found that the likelihood of recurrent symptoms — and especially the likelihood of hysterectomy — correlated with the depth of penetration of the adenomyotic disease. Wortman and Daggett (2001) found that operative hysteroscopy is useful in women after failed endometrial ablation and resection.³⁵ In a series of 26 women who had undergone endometrial ablation or resection and experienced failure characterized by intolerable pain, bleeding, or asymptomatic hsematometra, reoperative hysteroscopic surgery produced excellent results in achieving amenorrhoea and relief of pelvic pain, thereby avoiding hysterectomy in most patients. Adenomyosis was present in 58% of the specimens. It is therefore likely that, despite previous concerns, many women with superficial submucous adenomyosis may experience great symptomatic improvement by the hysteroscopic and third-generation procedures of endometrial ablation. Patients with deep endometrial penetration of >2.5 cm (deep adenomyosis) usually have persistent problems and

should be offered hysterectomy over repeat ablation. MRI or high-resolution ultrasound may be appropriate preoperative screening tools to determine the depth of adenomyosis and to select patients for endometrial ablation.³⁶

Intramural adenomyomata

Conservative surgery for deep uterine adenomyomata includes adenomyomectomy or myometrial reduction.³⁷ Excision may be difficult as it is extremely difficult to expose the lesion and determine the precise extent of the disease. The disease may be infiltrating close to the fallopian tubes or involve major vessels, and the lesions may be very vascular. Frequently surgery is preceded by a medical treatment with a GnRH agonist. The classical technique is almost the same as that of myomectomy. Fujishita et al (2003) described in a preliminary report a transverse H incision technique to improve exposure and allow careful examination by manual palpation and serial resection of myometrium containing adenomyotic tissue.³⁸ Comparing the classical technique versus the H incision the risk of endometrial perforation was reduced from 40% to 17%.

Liu et al (1998) reported on 26 patients with histologically proven adenomyosis who wanted to preserve their reproductive capacity.³⁹ Adenomyomectomy was performed in ten and partial resection in 16 patients. The rates of severe dysmenorrhoea and hypermenorrhoea after the operation were considered as significantly lower than those before, while also pregnancies and term deliveries were reported. Three patients relapsed after an average time of 50 months.

In recent years case reports of laparoscopic excision of myometrial adenomyomata and tumour reduction in patients with chronic pelvic pain have been published. The location of adenomyotic tissue may be difficult at laparoscopy. In one study the authors used MRI to diagnose and locate adenomyomata in ten symptomatic patients and successfully used laparoscopic bipolar coagulation in seven patients.⁴⁰ In the failed group one patient required resection, one patient required hysterectomy, and one patient refused further treatment. In another study the authors used in a symptomatic patient hydroultrasoundography to locate a cystic adenomyoma within the myometrium and performed a successful resection.⁴¹ In a third study the authors located the adenomyoma by preoperative MRI and achieved successful resection in three symptomatic patients.⁴²

Wang et al (2002) published a prospective pilot study of laparoscopic uterine artery ligation in 20 women with symptomatic adenomyosis. The outcome of the treatment was rated as satisfactory 6 months postoperatively by 15% of patients, but 45% were dissatisfied.⁴³ The poor satisfaction in this preliminary study suggests that the approach may not be effective for symptomatic adenomyosis.

Recently, a few authors reported on successful pregnancies or live births following surgical treatment in combination with GnRH agonists for adenomyosis and infertility. One study reported a live birth after conservative surgery for severe adenomyosis following diagnosis by MRI and preoperative treatment with GnRH-agonist therapy followed by resection of the localized lesion and postoperative therapy with danazol.⁴⁴ Another study reported a case of deep adenomyosis successfully treated by cytoreductive surgery and a subsequent 6-month course of GnRH-agonist therapy.⁴⁵ Lin et al (2000) diagnosed by ultrasound adenomyomata in the posterior uterine wall in four symptomatic patients with infertility and enlarged uteri.⁴⁶ At the end of a 6-month preoperative treatment with GnRH agonist all four enlarged uteri decreased to normal or near-normal size. After laparoscopic reductive surgery by adenomyomectomy three patients conceived within four menstrual periods. In one case

pregnancy was terminated by emergency caesarean section at 30 weeks of gestation because of threatened rupture of the uterus. Wang et al (2000) reported pregnancies in three patients treated with microsurgical resection of the visible adenomyotic areas followed by treatment of GnRH agonists.⁴⁷ The role of the combination of cytoreductive surgery and GnRH-agonist treatment in managing infertile women with adenomyosis is, however, far from clear. The approach seems to be attractive, but one must be aware of the surgical and obstetrical risks. One case was complicated by antepartum bleeding and threatened preterm labour.⁴⁵ It should, however, be noted that silent and spontaneous rupture of the uterus during labour has been reported in pregnant women with uterine adenomyosis.^{48,49}

Subserosal and retroperitoneal adenomyomata

Subserosal and retroperitoneal adenomyomata were first described by Sampson in 1921 in association with ovarian chocolate cysts: '*Sometimes they (foci of adenoma in the ovary) are invasive, and when so are apt to invade the uterus, forming an 'adenomyoma' or they may grow down between the rectum and the vagina, forming an 'adenomyoma of the rectovaginal septum' and may penetrate the vagina and appear in the posterior vaginal vault. In other cases they may extend through the wall of the rectum and sigmoid*'. In Sampson's series of 23 hysterectomy and bilateral salpingo-oophorectomy specimens foci of uterine subserosal adenomyota are described at the site of adhesions with the chocolate cyst in 18 (78%) cases.⁵⁰ Today, the adenomyotic nodule on the posterior side of the uterus, where the ovarian endometrioma is densely adherent to the uterus, can be detected preoperatively by MRI (see Chapter 11, Figure 16).⁵¹ Recently, Donnez and colleagues (2001) observed that retroperitoneal rectovaginal adenomyotic lesions frequently occur in the absence of ovarian endometriosis and have aptly described the lesions as 'retroperitoneal adenomyotic disease'.⁵²

Cul-de-sac obliteration is thought to arise from superficial peritoneal deposits, while in retroperitoneal adenomyosis the adenomyotic nodule is thought to arise from metaplasia of Mullerian remnants. It is important to remember that retroperitoneal endometriotic infiltration of the posterior pelvis is not destructive and that fat tissue is not invaded.⁵³ Itoga et al⁵⁴ recently described in detail the fibrosis and smooth muscle metaplasia that characterizes rectovaginal endometriosis. Immunostains were used to study 90 rectovaginal tissue specimens obtained from 37 affected women. Fibrosis was present in 89 specimens. The intensity of fibrosis differed greatly in specimens from area to area. In mild cases, collagen fibres were present around the endometriotic tissue, but in severe cases they extended into the surrounding fat and connective tissue. Increasing amount of endometriotic tissue correlated with increasing degree of fibrosis. Smooth muscle metaplasia, defined as aggregated smooth muscle not associated with blood vessels, was always detectable within the fibrotic areas. The degree of smooth muscle metaplasia correlated significantly with the degree of fibrosis.

Like uterine adenomyosis, these lesions have no capsule and are in continuity with the surrounding fibromuscular or muscular structures. 'Rectovaginal septum' endometriosis is often a misnomer as most rectovaginal nodules do not infiltrate the rectovaginal septum. However, adenomyotic lesions may be found in close proximity to the upper part of the septum, and the rectovaginal septum appears distinct and regular on MRI.⁵⁵ Involvement of the rectovaginal septum by endometriosis can be identified as an extension of the larger lesions located at the uterosacral ligaments, the pouch of

Douglas or the anterior rectal wall. Infiltrating posterior pelvis endometriosis can also extend into the cervix, rectal wall and laterally into the parametrium, and can even involve the ureters. The risk of obstructive uropathy increases in the presence of nodular posterior pelvic endometriosis larger than 3 cm.⁵⁶

On the basis of location defined by MR imaging and transrectal ultrasonography, Donnez et al (2004) distinguished three types of retroperitoneal adenomyosis (Figure 1).⁵⁷ The accurate preoperative diagnosis by imaging techniques and classification of the lesions is the key to therapy.

Type I: rectovaginal septum nodules. These lesions are situated within the rectovaginal septum between the posterior wall of the vaginal mucosa and the anterior wall of the rectal muscularis. A 'pure' rectovaginal septum nodule is observed in only 10% of cases of deep nodular lesions.

Type II: posterior vaginal fornix nodules. These lesions develop from the posterior fornix towards the rectovaginal septum.

Type III: diabolo-like retrocervical nodules. The lesions occur on the posterior site of the cervix and a small but well observed continuum exists with the adenomyotic lesion situated in the anterior rectal wall.

The concept of retroperitoneal adenomyoma covers not only the rectovaginal space but also the vesicovaginal space and the area extending laterally in the direction of the cardinal ligaments. Patients suffering from chronic pelvic pain and/or dysmenorrhoea, deep dyspareunia, dysuria or dyschizia should be investigated carefully by gynaecological examination and imaging techniques such as high-resolution ultrasound and

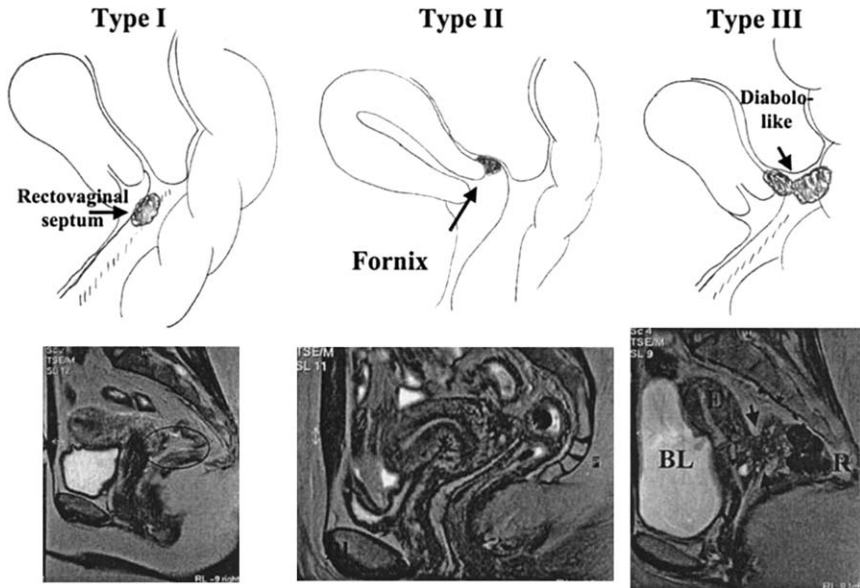


Figure 1. Classification of deep, adenomyotic lesions in the posterior pelvis. Type I: rectovaginal septum nodule. Type II: posterior vaginal fornix nodule. Type III: retrocervical, diabolo-like nodule. From Donnez et al (2004, *Best Practice & Research: Clinical Obstetrics & Gynaecology* 18: 329–348) with permission.

MRI. In case of large (>3 cm) rectovaginal adenomyoma, intravenous pyelography (IVP) should be performed in all patients considered at risk of obstructive uropathy before proceeding with the laparoscopic procedure.

Conservative surgery can be proposed in the majority of patients. The surgery may require excision of the nodular fibrotic tissue from the posterior vagina, rectum, posterior cervix, and uterosacral ligaments, as well as excision of rectal deposits.⁵⁵ In a very large series of 1125 cases, laparoscopic dissection was performed successfully in all cases. Laparoscopic rectal perforation occurred in seven cases (0.6%) that were diagnosed at the time of laparoscopy.

SUMMARY

Adenomyosis is a common, often debilitating condition in women in their reproductive years. The common presenting symptoms are painful and heavy periods and infertility, although many women are asymptomatic. The aetiology is unclear, and until recently a diagnosis was made only after invasive and destructive surgery. With the advent of improved imaging of the pelvic organs, and in particular magnetic resonance imaging, the diagnosis of adenomyosis is being made more frequently. Unfortunately, because the disease has been infrequently diagnosed prior to hysterectomy there are few well-designed studies of medical or surgical management. Management with hormonal treatment that aims to reduce the proliferation of endometrial cells is promising, but there is a paucity of well-designed studies to guide treatment. Hysterectomy or use of the LNG-IUS remains the mainstay of treatment.

Practice points

- diagnosis of adenomyosis is difficult
- many women are asymptomatic, although it frequently occurs in women already diagnosed with endometriosis
- imaging techniques have improved, and both ultrasound and magnetic resonance imaging can diagnose adenomyosis
- with the advent of improved diagnostics for adenomyosis there is the possibility of conservative treatment
- medical treatments that slow the proliferation of the endometrial glands within the myometrium appear to be promising, but further well-designed studies with long-term outcomes are awaited
- surgical treatment with hysterectomy remains the definitive approach, but there is the possibility of excision of adenomyotic nodules in combination with medical treatment in the future

Research agenda

- well-designed randomized controlled trial of medical and surgical treatments with long-term outcomes, including fertility and pregnancy

REFERENCES

1. Uduwela AS, Perera MAK, Aiqing L & Fraser IS. Endometrial-myometrial interface: relationship to adenomyosis and changes in pregnancy. *Obstet Gynecol Surv* 2000; **55**: 390–400.
- *2. Bergholt T, Eriksen L, Berendt N, Jacobsen M & Hertz JB. Prevalence and risk factors of adenomyosis at hysterectomy. *Hum Reprod* 2001; **16**: 2418–2421.
3. Tamai K, Togashi K, Ito T, Morisawa N, Fujiwara T & Koyama T. MR imaging findings of adenomyosis: correlation with histopathologic features and diagnostic pitfalls. *Radiographics* 2005; **25**: 21–40.
4. Nisolle M & Donnez J. Peritoneal rectovaginal endometriosis, ovarian endometriosis and adenomyotic nodules of the septum are three different entities. *Fertil Steril* 1997; **68**: 585–596.
- *5. Kunz G, Beil D, Huppert P, Noe M, Kissler S & Leyendecker G. Adenomyosis in endometriosis—prevalence and impact on fertility. Evidence from magnetic resonance imaging. *Hum Reprod* 2005; **20**: 2309–2316.
6. Azziz R. Adenomyosis: Current perspectives. *Obstet Gynecol* 1989; **16**: 221–235.
7. Andersson K, Odland V & Rybo G. Levonorgestrel-releasing and copper-releasing (Nova T) IUDs during five years of use: a randomized comparative trial. *Contraception* 1994; **49**: 56–72.
- *8. Fedele L, Bianchi E, Raffaelli R, Portuese A & Dorta M. Treatment of adenomyosis associated menorrhagia with a levonorgestrel-releasing intrauterine device. *Fertil Steril* 1997; **68**: 426–429.
9. Critchley HOD, Wang H, Kelly RW, Gebbie AE & Glasier AF. Progesterin receptor isoforms and prostaglandin dehydrogenase in the endometrium of women using a levonorgestrel-releasing intrauterine system. *Hum Reprod* 1998; **13**: 1210–1217.
10. Nilsson C, Haukkamaa M & Vierola H. Luukkainen. Tissue concentrations of levonorgestrel in women using a levonorgestrel-releasing IUS. *Clin Endocrinol* 1982; **17**: 529–536.
11. Suhonen SP, Holmstrom T, Allonen HO & Lahteenmaki P. Intrauterine and subdermal progesterin administration in postmenopausal hormone replacement therapy. *Fertil Steril* 1995; **63**: 336–342.
12. Cameron IT, Leask R, Kelly RW & Baird DT. The effects of danazol, mefenamic acid, norethisterone and a progesterone-impregnated coil on endometrial prostaglandin concentrations in women with menorrhagia. *Prostaglandins* 1987; **34**: 99–110.
13. Vercellini P, Frontino G, De Giorgi O et al. Comparison of a levonorgestrel-releasing intrauterine device versus expectant management after conservative surgery for symptomatic endometriosis: a pilot study. *Fertil Steril* 2003; **80**(2): 305–309.
14. Fedele L, Bianchi S, Zanconato G et al. Use of a levonorgestrel releasing intrauterine device in the treatment of rectovaginal endometriosis. *Fertil Steril* 2001; **75**(3): 485–488.
15. Fong YF & Singh K. Medical treatment of a grossly enlarged adenomyotic uterus with the levonorgestrel-releasing intrauterine system. *Contraception* 1999; **60**: 173–175.
16. Maia H, Maltez A, Studart E, Athayde C & Coutinho EM. Effect of menstrual cycle and hormonal treatment on ki-67 and bcl-2 expression and adenomyosis. *Gynecol Endocrinol* 2003; **20**: 127–131.
- *17. Igarashi M, Abe Y, Fukuda M, Ando A, Miyasaka M & Yoshida M. Novel conservative medical therapy for uterine adenomyosis with a danazol-loaded intrauterine device. *Fertil Steril* 2000; **74**: 412–413.
18. Shawki OA. Danazol loaded intrauterine device (D-IUD): a novel conservative management for uterine adenomyosis. *Middle East Fertility Journal* 2002; **7**: 214–220.
19. Huang W-S, Yng T-S & Yuan C-C. Successful pregnancy after treatment of deep adenomyosis with cytoreductive surgery and subsequent gonadotropin-releasing hormone agonist: a case report. *Chin Med J* 1998; **61**: 726–729.
20. Lin J, Sun C & Zheng H. Gonadotropin-releasing hormone agonists and laparoscopy in the treatment of adenomyosis and infertility. *Chin Med J* 2000; **113**: 442–445.
21. Noble LS, Simpson ER, Johns A & Bulun SE. Aromatase expression in endometriosis. *J Clin Endocrinol Metab* 1996; **81**: 174–179.
22. Bulun SE, Fang Z, Imir G, Gurates B, Tamura M, Yilmaz B, Langoi D, Amin S, Yang S & Deb S. Aromatase and endometriosis. *Semin Reprod Med* 2004; **22**: 45–50.
23. Ezaki K, Motoyama H & Sasaki H. Immunohistologic localization of estrone sulfatase in uterine endometrium and adenomyosis. *Obstet Gynecol* 2001; **98**: 815–819.

24. Soysal S, Soysal ME, Ozer S, Gul N & Gezgin T. The effects of post-surgical administration of goserelin plus anastrozole compared to goserelin alone in patients with severe endometriosis: a prospective randomized trial. *Hum Reprod* 2004; **19**: 160–167.
25. Amsterdam LL, Gentry W, Jobanputra S, Wolf M, Rubin SD & Bulun SE. Anastrozole and oral contraceptives: a novel treatment for endometriosis. *Fertil Steril* 2005; **84**: 300–304.
- *26. Furuhashi M, Miyabe Y, Katsumata Y, Oda H & Imai N. Comparison of complications of vaginal hysterectomy in patients with leiomyomas and in patients with adenomyosis. *Arch Gynecol Obstet* 1998; **262**: 69–73.
27. Cullen TS. *Adenomyoma of the Uterus*. Philadelphia: W.B. Saunders; 1908.
- *28. Gilks CB, Clement PB, Hart WR & Young RH. Uterine adenomyomas excluding atypical polypoid adenomyomas and adenomyomas of endocervical type: a clinicopathologic study of 30 cases of an underemphasized lesion that may cause diagnostic problems with brief consideration of adenomyomas of other female genital tract sites. *Int J Gynecol Pathol* 2000; **19**: 195–205.
- *29. Lee EJ, Joo HJ & Ryu HS. Sonographic findings of uterine polypoid adenomyomas. *Ultrasound Q* 2004; **20**: 2–11.
30. Bohlman ME, Ensor RE & Sanders RC. Sonographic findings in adenomyosis of the uterus. *AJR Am J Roentgenol* 1987; **148**: 765–766.
31. Togashi K, Nishimura K, Itoh K, Fujisawa I, Noma S, Kanaoka M, Nakano Y, Itoh H, Ozasa H, Fujii S et al. Adenomyosis: diagnosis with MR imaging. *Radiology* 1988; **166**: 111–114.
32. Löffler FD. Endometrial ablation and resection. *Curr Opin Obstet Gynecol* 1995; **7**: 290–294.
33. Pagedas AC, Boe IH & Perkins HE. Review of 24 cases of uterine ablation failure. *J Am Assoc Gynecol Laparosc* 1995; **2**: 239.
34. McCausland AM & McCausland VM. Depth of endometrial penetration in adenomyosis helps determine outcome of rollerball ablation. *Am J Obstet Gynecol* 1996; **174**: 1786–1793; 1793–1794.
35. Wortman M & Daggett A. Reoperative hysteroscopic surgery in the management of patients who fail endometrial ablation and resection. *J Am Assoc Gynecol Laparosc* 2001; **8**: 272–277.
36. McCausland V & McCausland A. The response of adenomyosis to endometrial ablation/resection. *Hum Reprod Update* 1998; **4**: 350–359.
37. Wood C, Maher P & Hill D. Biopsy diagnosis and conservative surgical treatment of adenomyosis. *Aust N Z J Obstet Gynaecol* 1993; **33**: 319–321.
38. Fujishita A, Masuzaki H, Khan KN, Kitajima M & Ishimaru T. Modified reduction surgery for adenomyosis. A preliminary report of the transverse H incision technique. *Gynecol Obstet Invest* 2004; **57**: 132–138.
39. Liu X, Huang H, Huang R, Lian L & Lang J. Clinical observation of conservative surgery for adenomyosis. *Zhongguo Yi Xue Ke Xue Yuan Xue Bao* 1998; **20**: 440–444.
40. Phillips DR, Nathanson HG, Milim SJ & Haselkorn JS. Laparoscopic bipolar coagulation for the conservative treatment of adenomyomata. *J Am Assoc Gynecol Laparosc* 1996; **4**: 19–24.
41. Nabeshima H, Murakami T, Terada Y, Noda T, Yaegashi N & Okamura K. Total laparoscopic surgery of cystic adenomyoma under hydroultrasonographic monitoring. *J Am Assoc Gynecol Laparosc* 2003; **10**: 195–199.
- *42. Morita M, Asakawa Y, Nakakuma M & Kubo H. Laparoscopic excision of myometrial adenomyomas in patients with adenomyosis uteri and main symptoms of severe dysmenorrhea and hypermenorrhea. *J Am Assoc Gynecol Laparosc* 2004; **11**: 86–89.
43. Wang CJ, Yen CF, Lee CL & Soong YK. Laparoscopic uterine artery ligation for treatment of symptomatic adenomyosis. *J Am Assoc Gynecol Laparosc* 2002; **9**: 293–296.
44. Ozaki T, Takahashi K, Okada M, Kurioka H & Miyazaki K. Live birth after conservative surgery for severe adenomyosis following magnetic resonance imaging and gonadotropin-releasing hormone agonist therapy. *Int J Fertil Womens Med* 1999; **44**: 260–264.
45. Huang WH, Yang TS & Yuan CC. Successful pregnancy after treatment of deep adenomyosis with cytoreductive surgery and subsequent gonadotropin-releasing hormone agonist: a case report. *Zhonghua Yi Xue Za Zhi (Taipei)* 1998; **61**: 726–729.
46. Lin J, Sun C & Li R. Gonadotropin releasing hormone agonists in the treatment of adenomyosis with infertility. *Zhonghua Fu Chan Ke Za Zhi* 1999; **34**: 214–216.

47. Wang PH, Yang TS, Lee WL, Chao HT, Chang SP & Yuan CC. Treatment of infertile women with adenomyosis with a conservative microsurgical technique and a gonadotropin-releasing hormone agonist. *Fertil Steril* 2000; **73**: 1061–1062.
48. Pafumi C, Farina M, Pernicone G, Russo A, Bandiera S, Giardina P & Cianci A. Adenomyosis and uterus rupture during labor. *Zhonghua Yi Xue Za Zhi (Taipei)* 2001; **64**: 244–246.
- *49. Bensaid F, Kettani F, el Fehri S, Chraïbi C & Alaoui MT. Obstetrical complications of adenomyosis. Literature review and two case reports. *J Gynecol Obstet Biol Reprod (Paris)* 1996; **25**: 416–418.
50. Sampson JA. Perforating hemorrhagic (chocolate) cysts of the ovary. *Arch Surg* 1921; **3**: 245–323.
51. Kinkel K, Brosens J & Brosens I. Preoperative investigations. In Sutton, Adamson & Jones (eds.). *Endometriosis: Surgical Management*. Taylor & Francis; 2006. pp. 71–86.
52. Donnez J, Donnez O, Squifflet J & Nisolle M. The concept of 'adenomyotic disease of the retroperitoneal space' is born. *Gynecol Endocrinol* 2001; **10**: 91–94.
53. Cornillie FJ, Oosterlynck D, Lauweryns JM & Koninckx PR. Deeply infiltrating pelvic endometriosis: histology and clinical significance. *Fertil Steril* 1990; **53**: 978–983.
54. Itoga T, Matsumoto T, Takeuchi H, Yamasaki S, Sasahara N, Hoshi T & Kinoshita K. Fibrosis and smooth muscle metaplasia in rectovaginal endometriosis. *Pathol Int* 2003; **53**: 371–375.
55. Chapron C, Liaras E, Fayet P et al. Magnetic resonance imaging and endometriosis: deeply infiltrating endometriosis does not originate from the rectovaginal septum. *Gynecol Obstet Invest* 2002; **53**: 204–208.
56. Donnez J, Nisolle M & Squifflet J. Ureteral endometriosis: a complication of rectovaginal endometriotic (adenomyotic) nodules. *Fertil Steril* 2002; **77**: 32–37.
- *57. Donnez J, Pirard C, Smets M, Jadoul P & Squifflet J. Surgical management of endometriosis. *Best Pract Res Clin Obstet Gynaecol* 2004; **18**: 329–348.